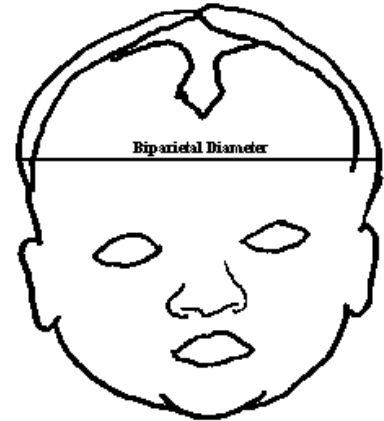


The Seven Cardinal Movements

Labor is a physical and emotional event for the laboring woman. For the infant, however, there are many positional changes that assist the baby in the passage through the birth canal. Because of the resistance met by the baby, positional changes are specific, deliberate and precise as they allow the smallest diameter of the baby to pass through a corresponding diameter of the woman's pelvic structure. Neither care providers nor the laboring woman is directly responsible for these position changes. The baby is the one responsible for these position changes ~ the *cardinal movements*.

Engagement or the entering of the *biparietal diameter* (measuring ear tip to ear tip across the top of the baby's head) into the pelvic inlet.



Descent

The baby's head moves deep into the pelvic cavity and is commonly called lightening. The baby's head becomes markedly molded when these distances are closely the same. When the occiput is at the level of the ischial spines, it can be assumed that the biparietal diameter is engaged and then descends into the pelvic inlet.

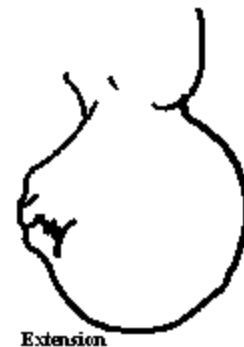Flexion

This movement occurs during descent and is brought about by the resistance felt by the baby's head against the soft tissues of the pelvis. The resistance brings about a flexion in the baby's head so that the chin meets the chest. The smallest diameter of the baby's head (or suboccipitobregmatic plane) presents into the pelvis.



Internal rotation

As the head reaches the pelvic floor, it typically rotates to accommodate for the change in diameters of the pelvis. At the pelvic inlet, the diameter of the pelvis is widest from right to left. At the pelvic outlet, the diameter is widest from front to back. So the baby must move from a sideways position to one where the sagittal suture is in the anteroposterior diameter of the outlet (where the face of the baby is against the back of the laboring woman and the back of the baby's head is against the front of the pelvis). If anterior rotation does not occur, the occiput (or head) rotates to the occipitoposterior position. The occipitoposterior position is also called *persistent occipitoposterior* and is the common cause for true back labor.



Extension

After internal rotation is complete and the head passes through the pelvis at the nape of the neck, a rest occurs as the neck is under the pubic arch. Extension occurs as the head, face and chin are born.

External rotation

After the head of the baby is born, there is a slight pause in the action of labor. During this pause, the baby must rotate so that his/her face moves from face-down to facing either of the laboring woman's inner thighs. This movement, also called *restitution*, is necessary as the shoulders must fit around and under the pubic arch.

It is at this point that *shoulder dystocia* may be identified. Shoulder dystocia occurs when the baby's shoulders are halted at the pelvic outlet due to inadequate space through which to pass. Mother's birthing babies who are identified as *macrosomatic* (in excess of 9.9 lbs.) are more likely to experience shoulder dystocia. Additionally, 15-30% of macrosomatic babies experiencing shoulder dystocia sustain some injury to the brachial plexus. Most of these injuries (80%) resolve by the baby's first birthday.

Commonly, the *McRobert's technique* is used to resolve shoulder dystocia. This technique involves a sharp flexing of the maternal thighs against the maternal abdomen to reduce the angle between the sacrum and the spine.

Expulsion

Almost immediately after external rotation, the anterior shoulder moves out from under the pubic bone (or symphysis pubis). The perineum becomes distended by the posterior shoulder, which is then also born. The rest of the baby's body is then born, with an upward motion of the baby's body by the care provider.